

LEIOMYOMA OF THE BREAST

ALBERTO A. DIAZ-ARIAS, MD, MARK A. HURT, MD, TIMOTHY S. LOY, MD, RICHARD M. SEEGER, MD, AND JOHN T. BICKEL, MD

Leiomyoma of the breast parenchyma proper is a rare neoplasm. This tumor occurs predominantly in late middle-aged women and can be clinically difficult to discern from carcinoma. Mammographically, the tumor lacks typical features of carcinoma, but this possibility cannot be absolutely excluded. Immunohistochemical, ultrastructural, and DNA characteristics are reported in a new case. Mammographic findings are reported for the first time. Immunoperoxidase findings with antibodies to muscle-specific actin, desmin, vimentin, S-100 protein, and cytokeratins, as well as the ultrastructural features, suggest a pure smooth muscle cell origin and not a myoepithelial cell origin. HUM PATHOL 20:396-399. © 1989 by W.B. Saunders Company.

Benign pure smooth muscle tumors of the breast parenchyma are uncommon if periareolar lesions are excluded. There are only eight such cases that we discovered in the literature.¹⁻⁸ This report describes an additional case of leiomyoma of parenchymal breast, its mammographic presentation, and the differential diagnosis. We further characterize this lesion immunohistochemically and ultrastructurally, analyze the tumor DNA content, and summarize the previously reported cases.

REPORT OF A CASE

The patient was a 69-year-old healthy white woman who was referred to the University of Missouri Hospital and Clinics (Columbia) for evaluation of a right breast mass of 1.5 months' duration. She denied pain, nipple discharge, or constitutional symptoms.

Received July 11, 1988, from the Departments of Pathology and Radiology, University of Missouri—Columbia; and the Department of Pathology, University of Texas Health Sciences Center, San Antonio. Accepted for publication October 31, 1988.

Key words: breast, leiomyoma, smooth muscle tumor, mammogram.

Address correspondence and reprint requests to John T. Bickel, MD, Department of Pathology, University of Missouri—Columbia, One Hospital Dr, Columbia, MO 65212.

© 1989 by W.B. Saunders Company.
0046-8177/89/2004-0017\$5.00/0

Physical examination revealed a firm, freely movable, 2.5-cm tumor deep in the right upper outer quadrant. There were no skin or nipple changes; no axillary or supraclavicular lymphadenopathy was noted. A xeromammo-

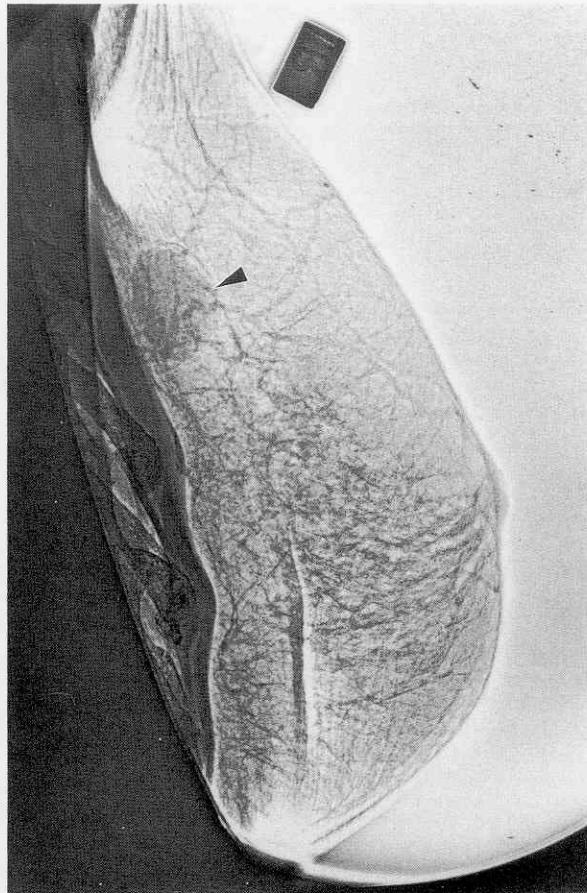


FIGURE 1. Xeromammogram showing a 3-cm circumscribed soft tissue mass well-removed from the nipple (axillary view).

gram was obtained. Axillary view of the right breast showed a circumscribed soft tissue mass deep in the upper outer quadrant, which measured approximately 3 cm in greatest dimension and was located 7 cm from the areola (with compression). No associated calcification, skin change, nipple retraction, or architectural distortion was noted; however, malignancy could not be ruled out (Fig 1). The tumor was extirpated and frozen section diagnosis was leiomyoma.

Twenty-five months postoperatively, the patient is doing well with no breast signs or symptoms.

MATERIALS AND METHODS

Tissue for light microscopy was fixed in 10% neutral buffered formalin, routinely processed, and embedded in paraffin. Sections were stained with hematoxylin-eosin, Masson's trichrome, Mallory's phosphotungstic acid-hematoxylin (PTAH), reticulin, and PAS with and without diastase digestion.

Immunohistochemical stains using antibodies against desmin, vimentin, S-100 protein, factor VIII-related antigen (all DAKO, Santa Barbara, CA), muscle-specific actin (Enzo, Biochemical, New York), and a cytokeratin cocktail of AE1/AE3 (Hybritech, San Diego) and MAK-6 (Triton, Biosciences, Alameda, CA) were used with the avidin-biotin-peroxidase complex technique. Digestion with 0.1% trypsin solution in pre-warmed distilled water containing 0.1% CaCl₂ (pH adjusted to 7.8 with 0.1 N NaOH) was performed for 15 minutes at 37°C before incubation with the antibodies against factor VIII-related antigen, cytokeratin, and desmin. Appropriate positive and negative controls were performed.

Using a modified technique from the original described by Hedley and colleagues, nuclear DNA content and DNA index in paraffin-embedded tissue were studied by flow cytometry.⁹

Tissue for electron microscopy was immediately fixed in 2% glutaraldehyde. The tissue was osmicated and embedded in Epon according to standard techniques. Ultrathin sections were examined with a Philips 300 electron microscope.

PATHOLOGIC FINDINGS

Gross Findings

The resection specimen was a discrete pink, 2 × 1.8 × 1.8 cm, firm, circumscribed mass, with a white, whorling, cut surface identical to uterine leiomyomata. No hemorrhage, necrosis, calcification, or areas of cystic change were present.

Light Microscopy

The lesion was well-circumscribed with a growth pattern of interlacing fascicles of smooth muscle cells showing oval nuclei with blunt ends, delicate chromatin, and occasional inconspicuous nucleoli. Cytoplasm was abundant and eosinophilic, with indistinct cell borders. No atypia or hypercellularity was present (Fig 2). No mitoses were found on examination of 50 high power fields (× 40 objective).

Special Stains

PAS with and without diastase digestion revealed glycogen in the tumor cells. Masson's trichrome and Mallory's PTAH revealed that the interweaving bundles of fibers

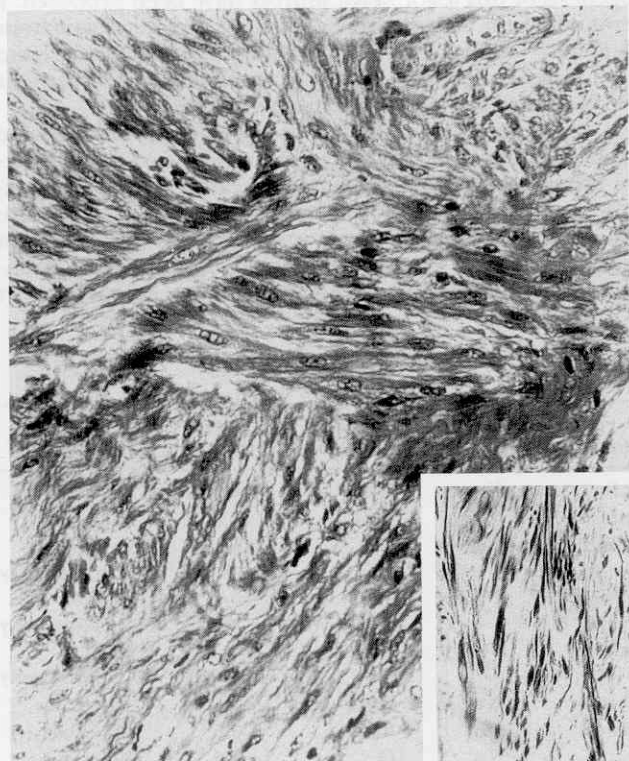


FIGURE 2. Interlacing fascicles of spindle cells with abundant cytoplasm and oval nuclei with blunt ends. (Hematoxylin-eosin stain; magnification × 200.) (Inset) Positive, diffuse cytoplasmic staining against desmin. (Desmin stain; magnification × 25.)

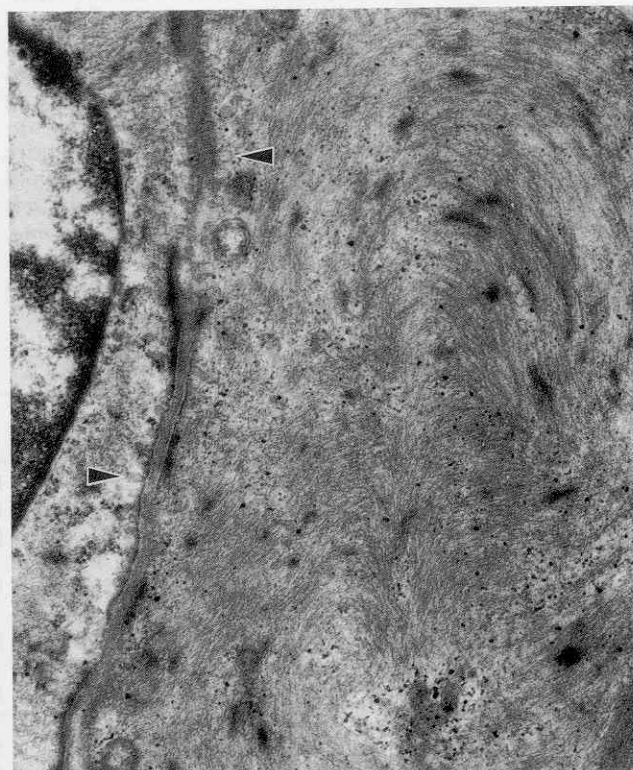


FIGURE 3. Prominent parallel and concentric arrays of thin filaments with focal densities, subplasmalemmal dense plaques, and pinocytotic vesicles (arrowheads). (Electron micrograph × 18,000.)

were separated by a modest amount of connective tissue with only a suggestion of longitudinally arranged striations. Reticulin stain showed reticulin investing most of the individual tumor cells. Immunoperoxidase for factor VIII-related antigen revealed numerous small endothelial lumina evenly distributed throughout the tumor; concentric layering of the smooth muscle was noted around many of the vascular spaces. Staining for desmin (Fig 2) and muscle-specific actin revealed strong, uniform, granular, intracytoplasmic positivity, while vimentin showed focal positivity. Anti-S-100 protein and cytokeratin stains were negative.

DNA Content

DNA cytometric analyses showed no evidence of an abnormal DNA stemline and a DNA index of 1.02.

Electron Microscopy

The nuclei of the tumor cells were round to fusiform with frequent folds and notches. Chromatin was moderately dispersed and frequently surrounded a compact nucleolus. The cytoplasm showed prominent parallel arrays of thin filaments with focal densities, frequent subplasmalemmal dense plaques, numerous pinocytotic vesicles, and focal aggregates of glycogen (Fig 3). Many cells were invested in a discontinuous external lamina. No cytoplasmic tonofilaments were identified. Focal intercellular desmosome-like structures, but no true desmosomes, were present.

DISCUSSION

Leiomyoma of the breast parenchyma is an exceedingly rare lesion when not associated with the nipple.^{8,10} In 1913, Strong described the first leiomyoma of the breast parenchyma.¹ Since that report, seven additional cases have been added to the literature,²⁻⁸ the last in 1971. An oft-cited report by Lieber actually addresses tumors of the skin and nipple, not the breast parenchyma proper.³ Azzopardi, in a treatise on the breast, briefly mentions the observation of a single "leiomyomatous" breast mass incorporating fat.¹⁰ From his description and illustrations, this mass appears to represent a myoid hamartoma and not a pure leiomyoma. Similarly, Haagensen⁸ described a 40-year-old woman with a 1-month history of a 3-cm mass in the left upper outer quadrant, which he designated as leiomyoma. Histologically, however, the tumor differed from leiomyoma in that it contained definite tubular epithelial elements

as part of the neoplasm. Haagensen referred to this as an "adenoleiomyoma" and considered it a unique neoplasm.

Data from previously reported cases (Table 1) have revealed parenchymal breast leiomyomata to occur primarily in late, middle-aged white women. The only complaints were either pain, discomfort, or recent growth, similar to cutaneous leiomyomata. The duration of the lesions ranged from 1 month to 26 years. All but two cases involved the right breast. There was no apparent breast quadrant predilection, but only one lesion was located in an inner quadrant. Neither nipple discharge nor retraction has been recorded, even in the centrally located tumors. No lymphadenopathy has been noted. The tumors have occurred singly, except in one case⁵; the range of size has been from 0.5 cm to 13 cm. Most tumors have been circumscribed, with a whorled cut surface and a firm consistency that is typical of uterine smooth muscle tumors. Histologic descriptions have been variable in length and content, but neither cytologic atypia, hypercellularity, high mitotic rate, nor necrosis has been reported.

The immunohistochemistry and ultrastructure of our case support pure smooth muscle cell origin and not myoepithelial origin. Immunoperoxidase staining for vimentin, desmin, and muscle-specific actin, commonly seen in smooth muscle cells, was positive. However, staining for S-100 protein and cytokeratin (positive in myoepithelial cells¹¹) was nonreactive. The ultrastructural features, such as numerous parallel arrays of thin filaments with focal densities, subplasmalemmal dense plaques, numerous pinocytotic vesicles, and external lamina, provide further support for smooth muscle differentiation. Ultrastructural findings characteristic of myoepithelial cells, such as cytoplasmic tonofilaments and true desmosomes, were not seen.¹¹

There continues to be controversy regarding the histogenesis of this lesion. Five sources have been proposed: a teratoid origin with extreme overgrowth of the myomatous elements³; embryologically displaced smooth muscle from the nipple³; angiomatous smooth muscle^{1,3}; a multipotent mesenchymal cell²; and myoepithelial cells.¹⁰

We see no evidence in our case, or in any other case, to support teratoid origin. Use of immunoperoxidase for factor III-related antigen aided in delineating small blood vessels from spaces caused by fixation artifact. Of note were those areas with angiocentric smooth muscle proliferation that was difficult to appreciate with routine hematoxylin-eosin-stained sections, which may be interpreted as support

TABLE 1. Clinical Data

Year	Reference	Sex	Race	Age	Duration (mo)	Symptoms	Recent Growth	Tumor Location	Size (cm)	Therapy
1913	Strong ¹	F	W	46	48	Discomfort	Yes	RUO	6	NG
1927	Schauder ²	F	W	34	1	Discomfort	Yes	RUO	3 × 2.5	Tylectomy
1932	Melnick ³	F	W	45	180	Pain (2 mo)	Yes	RLC	"Small grapefruit"	Simple mastectomy
1940	Leibowich and Lenz ⁴	F	W	58	204	Discomfort	No	C	13.8	Simple mastectomy
1942	Stein ⁵	F	W	54	312	Discomfort	Yes	RUI	4 × 3 (largest)	Radical mastectomy
1947	Craig ⁶	F	B	40	120	Pain (3 mo)	No	LLO	10	Tylectomy
1969	Libcke ⁷	F	W	50	1	Tenderness	No	RUC	0.5	Tylectomy
1971	Haagensen ⁸	F	NG	52	0.5	None	No	C	2.5	Tylectomy
1988	Present study	F	W	69	1.5	None	No	RUO	2	Tylectomy

Abbreviations: NG, not given; R, right; U, upper; O, outer; L, lower; C, center; I, inner; L, left.

for the angiomatous hypothesis of histogenesis in these tumors. The clinical presence of pain seen in some cases is also more frequent in leiomyomata of vascular origin but not usually present in genital leiomyomata, which include areolar tumors. Origin from a multipotent stem cell could not be refuted. Our immunohistochemical and ultrastructural findings showed no evidence of myoepithelial cell origin.

The differential diagnosis of this neoplasm should include adenoleiomyoma, cystosarcoma phylloides, fibroadenoma with prominent smooth muscle, fibromatosis, benign spindle cell tumor of the breast, fibrous histiocytoma, myoepithelioma, myoid hamartoma, and leiomyosarcoma. The first three lesions can be ruled out by thorough sectioning because they contain epithelial/ductal structures. Fibromatosis, benign spindle cell tumor of the breast, fibrous histiocytomas, and myoepitheliomas are lesions composed of varying mixtures of fibroblasts, myofibroblasts, undifferentiated mesenchymal cells, and myoepithelial cells^{8,10,11} rather than purely smooth muscle cells. Myoid hamartoma of the breast, likened by some to leiomyoma of the breast, incorporates as part of the tumor fibrous tissue and mature adipose tissue in addition to smooth muscle.¹⁰

Perhaps the most important differential is with leiomyosarcoma of the breast. Histologically, this tumor shows prominent cytologic atypia, two to 16 mitoses per ten high power fields, atypical mitoses, vascular invasion, and necrosis.¹² Rare mitoses have been described in some of the leiomyomata of the breast.¹⁻³ However, none of the reported cases has shown high mitotic rates, atypical mitoses, vascular invasion, necrosis, or high-grade cytologic atypia. While definitive histologic guidelines to determine the malignant potential of smooth muscle tumors of the breast parenchyma await more experience with these lesions, it would seem that the criteria used for soft tissue smooth muscle neoplasms (mitotic count above five per ten high power fields, high cellularity, prominent atypia, vascular invasion, and infiltration) would be too lenient, as two of

the cases metastasized 15 and 19 years later, in spite of maximal mitotic rates of two to three mitoses per ten high power fields.¹²

DNA analysis of benign smooth muscle tumors of the gastrointestinal tract and the uterus has been shown to have discriminatory as well as prognostic significance.⁹ Our findings of diploid DNA content with a DNA index of 1.02 suggest a benign behavior in this breast lesion. However, we do not advocate sole reliance on DNA analysis to determine biologic behavior, but view it as a useful ancillary tool that complements conventional histologic parameters.

Acknowledgment. Special thanks to L. Henry and W. Caldwell, MD, for their assistance with the DNA analysis; to P. Stapleton and B. Payne for their secretarial help; and to H. Haibach, MD, for translating the German references.

REFERENCES

1. Strong LW: Leiomyoma of the breast. *Am J Obstet* 68:53-55, 1913
2. Schauder H: Uber leiomyome der brustdruse. *Dtsch Z Chir* 205:58-68, 1927
3. Melnick PJ: Fibromyoma of the breast. *Arch Pathol* 14:794-798, 1932
4. Lebowich RJ, Lenz G: Primary fibromyoma of the breast. *Am J Cancer* 38:73-75, 1940
5. Stein RJ: Fibroleiomyoma of the breast. *Arch Pathol* 33:72-74, 1942
6. Craig JM: Leiomyoma of the female breast. *Arch Pathol* 44:314-317, 1947
7. Libcke JH: Leiomyoma of the breast. *J Pathol* 98:89-91, 1969
8. Haagensen CD: Nonepithelial neoplasms of the breast, in Haagensen CD (ed): *Diseases of the Breast*, ed 2. Philadelphia, Saunders, 1971, pp 292-325
9. Tsushima K, Stanhope CR, Gaffey TA, et al: Uterine leiomyosarcomas and benign smooth muscle tumors: Usefulness of nuclear DNA patterns studied by flow cytometry. *Mayo Clin Proc* 63:248-255, 1988
10. Azzopardi JG: Problems in breast pathology, in Bennington JL (ed): *Major Problems in Pathology*, vol II. Philadelphia, Saunders, 1979, pp 368-395
11. Thorner PS, Khan HJ, Baumal R, et al: Malignant myoepithelioma of the breast: An immunohistochemical study by light and electron microscopy. *Cancer* 57:745-750, 1986
12. Nielsen BB: Leiomyosarcoma of the breast with late dissemination. *Virchows Arch [A]* 403:241-245, 1984